

# Management of the paediatric patient with acute head trauma FREE

Catherine A Farrell, Canadian Paediatric Society,  
Acute Care Committee

*Paediatrics & Child Health*, Volume 18, Issue 5, May 2013, Pages  
253–258, <https://doi.org/10.1093/pch/18.5.253>

**Published:** 03 May 2013

## Abstract

Head trauma leading to brain injury is an important cause of morbidity and mortality in childhood. Injury severity is related to the mechanism of trauma, which itself varies with age. The vast majority of head trauma in paediatric patients is mild, requires no specific therapy and leaves no sequelae. However, it is important to identify individuals at risk of significant injury, and thus in need of specific evaluation. The purpose of this statement is to describe issues related to head trauma in infants, children and youth, including clinical manifestations, initial management priorities, guidelines for imaging, and subsequent observation and treatment. It addresses the evaluation of patients with acute trauma to the head at the time of initial assessment; it does not describe the subsequent management of such patients in the paediatric intensive care unit.

---

## Issue Section: [Position Statement](#)

Head trauma leading to brain injury is an important cause of morbidity and mortality in childhood. Estimates of the incidence in paediatric patients vary according to definition and methodology; however, the annual rate ranges from 130 to 200 cases per 100,000 population, leading to at least 20,000 emergency department (ED) visits in Canadian paediatric hospitals per year.<sup>[1]–[3]</sup> In the United States, head trauma is estimated to lead to >470,000 emergency department visits and

35,000 hospital admissions annually.[4] Head trauma is thus one of the most common reasons for consultation in the ED.

**Only a small proportion of patients with head trauma will be found to have a traumatic brain injury (TBI).** This term is used to describe the symptoms and signs that result from trauma to the brain itself, which may or may not be associated with findings of injury on imaging studies. In sports-related concussion, it is well recognized that significant symptoms and impaired functioning may persist for a considerable length of time after the traumatic event. The clinical significance of intracranial lesions may be defined in a variety of ways, such as the need for hospitalization or neurosurgical intervention. In one large series of children presenting to the ED in children's hospitals in Italy, the risk of fatal and nonfatal traumatic brain injury was 0.5 and 5.2 per 1000 children with closed head trauma, respectively.[5]

The unique anatomy of children may make them more likely to develop an intracranial lesion due to head trauma. They have a larger head-to-body size ratio, a thinner cranial bone and less myelinated neural tissue.[6] Paediatric patients with traumatic brain injury more commonly develop a pattern of diffuse axonal injury and secondary cerebral edema compared with adults. Lesions actually requiring neurosurgical intervention, such as evacuation of a hematoma, are relatively rare.

**The most common causes of head trauma in children and youth presenting to Canadian EDs are:[2]**

- Falls
- Sports-related injuries
- Being hit on the head, by an object or by colliding with an obstacle
- Injuries involving the use of a bicycle
- Injuries involving motor vehicles, especially as a pedestrian.

Intracranial injury is more frequent following falls from a height above three feet (91 cm, or twice the length/height of the individual), involvement in a motor vehicle accident (either as a

passenger or a pedestrian) or impact from a high-velocity projectile.[7]

## Clinical manifestations

---

Children with head trauma may present with a variety of symptoms, including:

- Headache
- Amnesia
- Impaired level of consciousness, disorientation or confusion
- Vomiting
- Loss of consciousness
- Blurred vision
- Seizures

Younger children may present with lethargy or irritability. It is difficult to conclude from published studies which, if any, single clinical symptom or sign is a reliable predictor of intracranial injury.

However, signs that have been particularly associated with intracranial injury include:

- Prolonged loss of consciousness or impaired level of consciousness
- Disorientation or confusion; amnesia
- Worsening headache
- Repeated or persistent vomiting

## Classification of the severity of head trauma

---

The Glasgow Coma Scale (GCS) ([Table 1A](#))[8] is a validated tool used to evaluate level of consciousness. The Paediatric Glasgow Coma Scale ([Table 1B](#)) has been shown to be particularly useful in preverbal children.[9]

For the purposes of these guidelines, head trauma is classified according to GCS as follows:

- GCS 14 to 15: Minor head trauma
- GCS 9 to 13: Moderate head trauma
- GCS  $\leq$ 8: Severe head trauma

Minor head trauma accounts for the majority of paediatric patients presenting for medical assessment for possible head injury. Patients with moderate or severe head trauma are more likely to exhibit intracranial pathology and require either supportive care or specific treatment in a hospital setting.

**TABLE 1A** Standard Glasgow Coma Scale (GCS)

Eye opening		Best verbal response		Best motor response	
Spontaneous	4	Oriented	5	Follows commands	6
To verbal stimuli	3	Confused	4	Localized pain	5
To pain	2	Inappropriate words	3	Withdraws to pain	4
None	1	Incomprehensible sounds	2	Flexion to pain	3
		None	1	Extension to pain	2
				None	1

*Adapted from reference [8]*

**TABLE 1B** Paediatric Glasgow Coma Scale (GCS)

Eye opening		Best verbal response		Best motor response	
Spontaneous	4	Coos, babbles	5	Normal spontaneous movement	6
To speech	3	Irritable, cries	4	Withdraws to touch	5
To pain	2	Cries to pain	3	Withdraws to pain	4
None	1	Moans to pain	2	Abnormal flexion	3
		None	1	Abnormal extension	2
				None	1

Adapted from reference [9]

## Initial management priorities

**The first priority is to stabilize vital signs.** An important goal of stabilization is to avoid secondary injury to the traumatized brain from hypoxia, hypotension, hyperthermia or raised intracranial pressure. A structured approach to the assessment of airway, breathing, circulation and disability (ABCD) is described in [Table 2.\[10\]](#) On occasion, early and definitive treatment of a primary intracranial injury may be required (eg, in some cases of epidural hematomas).

A pertinent history should also be obtained. Elements to include are:

- The mechanism of head trauma, whether witnessed or not;
- The state in which the patient was found, including loss of consciousness or seizures;
- Presenting symptoms, especially impaired level of consciousness, disorientation or confusion, amnesia, worsening headache or repeated vomiting; and
- Medical history of head injury, neurological disorders, medication use and bleeding diathesis.

**The possibility of abusive head trauma in infants and children needs to be considered**, especially in situations of altered level of consciousness without obvious cause, or when the clinical findings are not compatible with the history provided.[11]

Abusive head trauma may not be recognized initially, due to variable modes of presentation and the typically young age of victims.[12] Delays in recognizing traumatic brain injury in this context may lead to relatively poor outcomes.

The depth of investigation, including cerebral imaging, and the need for observation, hospitalization or specific intervention, largely depend on the clinical state of the patient at the time of initial assessment (Figure 1).

**TABLE 2** Assessment and stabilization (ABCD)

<b>Airway (A)</b>
Consider possible injury to the cervical spine
Maintain head and neck in a neutral position
Immobilization: Sandbags, intravenous solution bags, towel rolls (younger patients)
Age-appropriate rigid cervical collar or manual in-line immobilization (older patients)
Orotracheal intubation if cannot maintain airway adequately with positioning and after suctioning
<b>Breathing (B)</b>
Intubation if unable to maintain adequate oxygenation and ventilation, despite provision of supplemental oxygen
Use rapid-sequence induction technique
Maintain cervical spine precautions
<b>Circulation (C)</b>
Hemodynamic instability unlikely to be caused by intracranial injury alone (exception: Significant intracranial or scalp bleeding in a young infant).

If present:

- Investigate extracranial lesions causing hemorrhagic or hypovolemic shock
  - Insert two large-bore intravenous catheters; fluid bolus of 20 mL/kg of normal saline
  - Repeat until vital signs improve.
- 

### **Disability (D)**

---

Perform rapid assessment, including:

- Glasgow Coma Scale score adapted to age
  - pupil size and reactivity to light
  - tone, reflex and movement of all four limbs
  - fontanelle (infants)
  - signs of basal skull fracture: Periorbital ecchymosis ('raccoon eyes'), ecchymosis over the mastoid bone (Battle's sign), obvious leakage of CSF from the nose or ears, hemotympanum. If one or more of these signs is present, no tube should be placed by the nasal route
- 

*Adapted from reference [10]. CSF Cerebrospinal fluid*

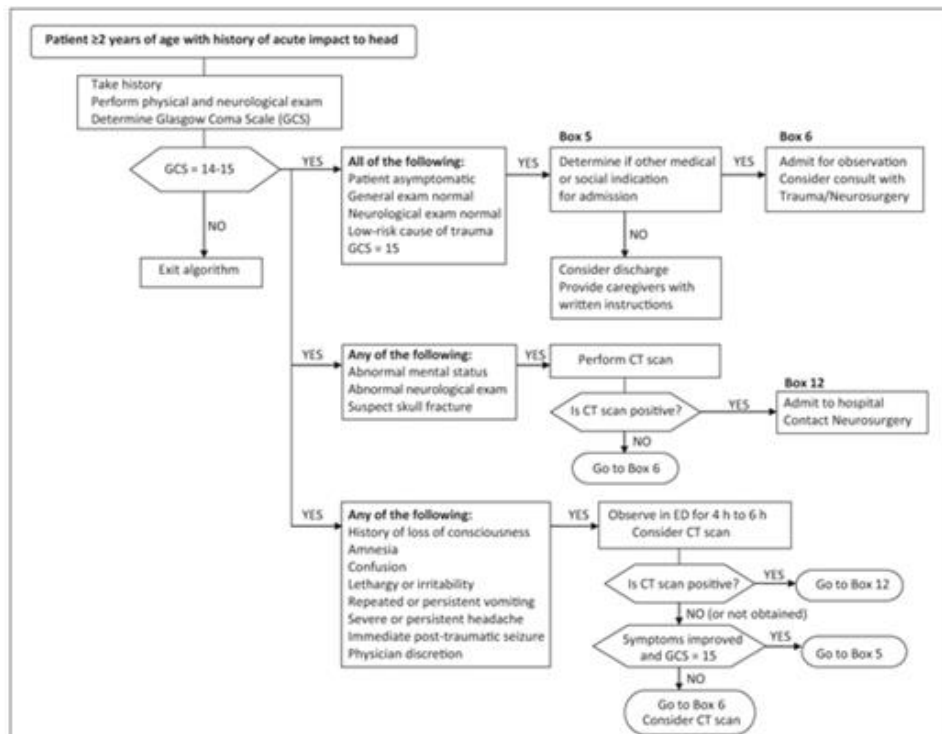


Figure 1) Algorithm for the management of the paediatric patient  $\geq 2$  years of age with minor head trauma. CT Computed tomography; ED Emergency department

[Full printable version of Figure 1](#)

## Imaging

### Indications for skull x-rays

While the presence of a linear skull fracture appears to be an independent risk factor for intracranial lesions,<sup>[13]</sup> skull x-rays need not be performed routinely in all patients.<sup>[14],[15]</sup>

Children younger than two years of age with head trauma present particular challenges. Clinical assessment of their neurological status may be limited by their developmental level, particularly in the preverbal stage. The incidence of skull fracture following minor head injury may be as high as 11% in this age group<sup>[16]</sup> but obtaining imaging studies, especially computed tomography (CT) scans, may require sedation. Guidelines for evaluating children younger than two years of age with apparently minor head trauma have been published.<sup>[17]</sup> These have supported the recommendation that skull x-rays should be performed in the presence of a large, boggy hematoma in a child younger than two years of age.<sup>[14],[16],[17]</sup>



While an obvious penetrating lesion or suspected depressed skull fracture in an older patient is an indication for skull x-ray, a CT scan is more commonly performed.

If elements of the history or physical examination raise the suspicion of child abuse, skull x-rays are indicated as part of the investigation. Detailed discussion of abusive head trauma is beyond the scope of this statement and has been addressed well in other documents.[\[11\]](#)

## Indications for CT scan

All patients presenting with moderate or severe head trauma should undergo a cranial CT scan. However, there is considerable debate about which patients with minor head trauma require a CT scan, given the potential for late deterioration resulting from delayed diagnosis of an intracranial injury and the relative unreliability of clinical signs in predicting intracranial injury.[\[18\]](#) The low rate of positive findings on CT scan, the need to sedate some patients in order to perform the examination, and concern about the risk of radiation exposure[\[19\]](#) have prompted the development of clinical prediction rules to guide clinicians in deciding for whom a scan should be performed. All of these rules involve some combination of variables based on the mechanism of trauma, signs and symptoms on initial assessment, or status after a period of observation. Recent systematic reviews have criticized their heterogeneity and lack of prospective validation in multicentre cohorts.[\[20\]](#),[\[21\]](#)

The largest study published to date on this issue is from the Pediatric Emergency Care Applied Research Network.[\[22\]](#) This study included 42,412 patients from 25 sites. This group's approach differed from previous studies in identifying elements whose *absence* would obviate the need for a CT scan. While highly sensitive and relatively specific, widespread application of these algorithms may lead to greater, rather than less, use of CT scans.[\[23\]](#)

Members of the Pediatric Emergency Research Canada Head Injury Study Group[\[2\]](#) derived the Canadian Assessment of Tomography for Childhood Head Injury (CATCH) rule, by means

of a prospective cohort study involving 3886 children presenting with symptomatic minor head trauma to 10 Canadian paediatric teaching institutions. The CATCH rule is outlined in [Table 3](#). The seven high- and medium-risk factors were shown in a subsequent prospective validation study to be 98% sensitive (95% CI 95% to 99%) for predicting acute brain injury, and would require that 38% of patients undergo CT.[\[24\]](#)

**TABLE 3** Canadian Assessment of Tomography for Childhood Head Injury: The CATCH rule

---

**CT of the head is required for children with a minor head injury\* plus any one of the following findings:**

---

**High risk (need for neurological intervention)**

1. Glasgow Coma Scale score <15 at 2 h after injury
  2. Suspected open or depressed skull fracture
  3. History of worsening headache
  4. Irritability on examination
- 

**Medium risk (brain injury on CT scan)**

1. Any sign of basal skull fracture (eg, hemotympanum, ‘raccoon’ eyes, otorrhea or rhinorrhea of cerebrospinal fluid, Battle’s sign)
  2. Large, boggy hematoma of the scalp
  3. Dangerous mechanism of injury (eg, motor vehicle collision, fall from a height  $\geq 3$  feet ( $\geq 91$  cm) or down five stairs, falling from a bicycle without a helmet)
- 

Adapted from reference [\[2\]](#).

\* *Minor head injury is defined as an injury sustained within the past 24 h associated with witnessed loss of consciousness, definite amnesia, witnessed disorientation, persistent vomiting (more than one episode) or persistent irritability (in a child younger than two years of age) in a patient with a Glasgow Coma Scale score of 13 to 15. CT Computed tomography*

## Elements on history or physical examination that should motivate the clinician to order a CT scan:

### Absolute indications:

- Focal neurological deficit on physical examination
- Clinically suspected open or depressed skull fracture, or a widened or diastatic skull fracture observed on x-ray

### Relative indications:

- Abnormal mental status: GCS <14 at any point from time of initial assessment onward, or GCS <15 at 2 h after injury
- Clinical deterioration over 4 h to 6 h of observing a symptomatic patient in the ED, including worsening headache or repeated vomiting
- Signs suggestive of a basal skull fracture
- Large, boggy scalp hematoma in child  $\geq 2$  years of age; in younger children, consider performing a skull x-ray first
- Mechanism of trauma raising suspicion for serious injury (eg, falling from a height, a motor vehicle collision in which speed was a factor, or impact with a projectile, such as a gunshot or a metal fragment)
- Persistent irritability in a child <2 years of age
- Seizures at the time of the event or later
- Known coagulation disorder

## Management after initial assessment

---

### Minor head trauma (GCS 14 or 15)

Asymptomatic patients may be discharged home to the care of reliable parents or guardians. Written instructions describing signs to watch for (eg, worsening headache, persistent vomiting, difficulty in awakening), who to contact in such a case and when to return for follow-up, should be provided.

**If after initial evaluation there is headache or repeated vomiting, or there is a history of loss of consciousness at the time of trauma, a period of clinical observation, with reassessment, is indicated.** If there is improvement in symptoms and the GCS is 15, the patient may be discharged home with parental instructions as above. If there is no improvement, the patient should be admitted to hospital with evaluation of vital signs and level of consciousness every 2 h to 4 h. Intravenous rehydration should be provided for patients with persistent vomiting. Persistent symptoms after 18 h to 24 h of hospitalization may indicate a cranial CT scan, if not already performed. A CT scan with positive findings should be discussed with a neurosurgeon, and consulting a clinician experienced in the management of head trauma may be appropriate for patients with negative CT scans but experiencing persistent symptoms.

**In the child younger than two years of age, and particularly in children younger than 12 months of age, greater caution is advised.** The challenges of their clinical assessment and the importance of identifying abusive trauma should lead clinicians to observe these patients for a longer period, with frequent reassessments. Trivial head trauma in an asymptomatic, ambulatory toddler is compatible with discharge from the ED; this may not be the case for an infant or baby. The presence of a widened or diastatic skull fracture (>4 mm) increases the risk of developing a leptomenigeal cyst, and follow-up of these patients should be arranged.<sup>[25]</sup> In cases of suspected abusive head trauma, hospitalization may be indicated and referral to the local child protection authorities is always required.

## **Moderate head trauma (GCS 9 to 13)**

**All patients with moderate head trauma should undergo imaging by CT scan.** Skull x-rays may also be indicated. They should be admitted to hospital and consultation with a neurosurgeon or clinician experienced in the management of head trauma is advised. Depending on the CT scan findings and the evolution of neurological status, admitting these patients to a paediatric intensive care unit may be needed to provide closer monitoring. This is particularly true for patients at the lower

end of the GCS spectrum (GCS 9 to 10). The decision to transfer a patient with a moderate head injury to a tertiary care centre must be individualized, based on clinical judgment and local resources, and should be discussed with a paediatric intensive care or trauma team, or both.

## **Severe head trauma (GCS $\leq$ 8)**

**Once the patient with a severe head injury has been stabilized, including intubation, a cranial CT scan should be performed.** Severe traumatic brain injury is a complex and challenging emergency. Patients with severe head trauma are at risk of raised intracranial pressure (ICP). Raised ICP may result from the mass effect of localized bleeding, as in the case of epidural and subdural hematomas, or be produced by vasogenic edema from diffuse axonal injury. In the acute setting, measures aimed at maintaining a normal ICP and cerebral perfusion pressure are appropriate.[\[26\]](#)

### **Management should include:**

- Continuous monitoring of vital signs and, if possible, end-tidal CO<sub>2</sub>
- Mechanical ventilation to maintain normal oxygenation and ventilation
- Maintenance of a normal core temperature
- Providing sedation and analgesia, particularly during procedures and transport
- Fluid administration as required to maintain normovolemia and avoid hypotension.

**Patients with severe head trauma require referral to a trauma centre with neurosurgical and paediatric critical care services.** [\[27\]](#) During transport, continuous monitoring of neurological, respiratory and hemodynamic status is essential, and treatment modalities for emergency management of raised ICP should be available.

## Post-traumatic seizures

---

The majority of post-traumatic seizures in children occur within the first 24 h, and rarely beyond seven days. Factors increasing the risk of post-traumatic seizures may include younger age,[28] severe head trauma (GCS  $\leq$ 8), cerebral edema, subdural hematoma, and open or depressed skull fractures.[29] The incidence of early post-traumatic seizures ranges from 5% to 6.5% but may be as high as 30% to 35% in severe head trauma.[29],[30] It is possible that abnormal mental status at initial assessment following a head trauma is due to a postictal state.

Post-traumatic seizures may contribute to secondary brain injury, with the exception of those occurring immediately after the head trauma: so-called 'impact seizures'. **Patients with impact seizures or an isolated post-traumatic seizure shortly after the event, but whose neurological examination and imaging are normal, are at low risk of further complications and may be discharged.**[31]

The acute treatment of post-traumatic seizures is identical to that of acute seizures occurring in other contexts. The [emergency management of paediatric patients with generalized convulsive status epilepticus](#) has been described in a recent statement from the Canadian Paediatric Society.[32]

Administering phenytoin to prophylax for post-traumatic seizures in paediatric head trauma patients is not proven effective[33],[34] but it is still used frequently to treat post-traumatic seizures and to prophylax in patients with severe head trauma.[27]

## Prognosis

---

The majority of patients with minor head injury do not exhibit intracranial pathology and their symptoms will resolve quickly. Nevertheless, the literature regarding [sports-related concussive injury](#) clearly demonstrates that some patients will continue to experience symptoms of varying intensity for days

or weeks following the concussion, with effects on global functioning and school performance.[35]

With a documented intracranial injury, indicators of poor prognosis include clinical severity at initial presentation, especially a GCS  $\leq 5$ , and the presence of raised ICP. Research is underway to assess the validity of serum or cerebral spinal fluid (CSF) markers of severity of injury, as well as early examinations of cerebral physiology such as cerebral oximetry and somatosensory-evoked potentials.[36],[37]

Other elements influencing prognosis following traumatic brain injury include the presence and severity of injuries at other body sites, pre-injury attention-deficit-hyperactivity disorder, and socioeconomic status.[38] Difficulties in concentration, attention and behaviour may lead to problems with social functioning long after the time of the injury.[18]

## Prevention

---

Health care practitioners have numerous opportunities to provide age-appropriate anticipatory guidance around risk factors for head trauma in children. The CPS advocates for public policy and legislation to ensure, for example, helmet use in sporting activities, child restraint use in vehicles and the ban on baby walkers in Canada. Such measures have proven successful in reducing both the incidence and severity of head trauma in paediatric patients.[39] **Clinicians treating infants, children and youth should include injury prevention when counselling families.**

## Conclusions

---

Head trauma is a frequent occurrence in childhood and adolescence, with most injuries being minor and without sequelae. A systematic approach to the clinical assessment of the patient presenting with head trauma is recommended, with investigations being conducted according to the symptoms, signs and estimated likelihood of intracranial pathology. Most

patients can be either discharged or observed in hospital for a short period. Severely injured children require immediate stabilization, close surveillance and continuous monitoring to prevent secondary lesions that may aggravate the consequences of the primary brain injury.

## Acknowledgements

---

This position statement has been reviewed by the Injury Prevention Committee, Healthy Active Living and Sports Medicine Committee, Community Paediatrics Committee and the Paediatric Emergency Medicine Section of the Canadian Paediatric Society.

## CPS ACUTE CARE COMMITTEE

---

**Members:** Adam Cheng MD; Isabelle M Chevalier MD (Board Representative); Catherine A Farrell MD; Jeremy N Friedman MD; Laurel Chauvin-Kimoff MD (Chair); Angelo Mikrogianakis MD (past Chair); Oliva Ortiz-Alvarez MD

**Liaisons:** Dominic Allain MD, CPS Paediatric Emergency Medicine Section; Marilyn Monk, Canadian Association of Paediatric Health Centres; Jennifer Walton MD, CPS Hospital Paediatrics Section

**Principal author:** Catherine A Farrell MD

## References

---

1. Gordon KE Pediatric minor traumatic brain injury. *Semin Ped Neurol* 2006;13(4):243-55.  
[Google Scholar](#)   [Crossref](#)
2. Osmond MH, Klassen TP, Wells GA, et al. ; for the Pediatric Emergency Research Canada (PERC) Head Injury Study Group CATCH: A clinical decision rule for the use of computed tomography in children with minor head injury. *CMAJ* 2010;182(4):341-8.  
[Google Scholar](#)   [Crossref](#)   [PubMed](#)



3. Mehta S Neuroimaging for paediatric minor head injuries. *Paediatr Child Health* 2007;12(6):482–4.  
[Google Scholar](#)   [Crossref](#)   [PubMed](#)
4. Faul M, Xu L, Wald MM, Coronado YG Traumatic Brain Injuries in the United States, Emergency Department visits, Hospitalizations and Deaths, 2002–2006. Atlanta: Centers for Disease Control, National Center for Injury Prevention and Control, 2010.  
[Google Scholar](#)
5. Da Dalt L, Marchi AG, Laudizi L, et al. Predictors of intracranial injuries in children after blunt head trauma. *Eur J Pediatr* 2006;165(3):142–8.  
[Google Scholar](#)   [Crossref](#)   [PubMed](#)
6. Sookplung P, Vavilala MS What is new in pediatric traumatic brain injury? *Curr Opin Anesthesiol* 2009;22(5):572–8.  
[Google Scholar](#)   [Crossref](#)
7. Dunning J, Daly JP, Lomas JP, Lecky F, Batchelor J, Mackway-Jones K Children’s head injury algorithm for the prediction of important clinical events study group Derivation of the children’s head injury algorithm for the prediction of important clinical events decision rule for head injury in children. *Arch Dis Child* 2006;91(11):885–91.  
[Google Scholar](#)   [Crossref](#)   [PubMed](#)
8. Teasdale G, Jennett B Assessment of coma and impaired consciousness. A practical scale. *Lancet* 1974;2(7872):81–4.  
[Google Scholar](#)   [Crossref](#)   [PubMed](#)
9. Holmes JF, Palchak MJ, MacFarlane T, Kuppermann N Performance of the Pediatric Glasgow Coma Scale in children with blunt head trauma. *Acad Emerg Med* 2005;12(9):814–9.  
[Google Scholar](#)   [Crossref](#)   [PubMed](#)
10. American College of Surgeons Committee on Trauma eds. Advanced Trauma Life Support for Doctors Manual, 8th edition. Chicago: American College of Surgeons, 2008.  
[Google Scholar](#)
11. Canadian Paediatric Society, Child and Youth Maltreatment Section, Guidelines Working Group Multidisciplinary Guidelines on the Identification, Investigation and Management of Suspected Abusive Head Trauma. Ottawa: Canadian Paediatric Society, 2007.

[Google Scholar](#)

12. King WJ, MacKay, M, Simick A; Canadian Shaken Baby Study Group  
Shaken baby syndrome in Canada: Clinical characteristics and outcomes of hospital cases. *CMAJ* 2003;168(2):155–9.  
[Google Scholar](#)    [PubMed](#)
13. Erlichman DB, Blumfield E, Rajpathak S, Weiss A Association between linear skull fractures and intracranial hemorrhage in children with minor head trauma. *Pediatr Radiol* 2010;40(8):1375–9.  
[Google Scholar](#)    [Crossref](#)    [PubMed](#)
14. Quayle KS, Jaffe DM, Kuppermann N, et al. Diagnostic testing for acute head injury in children: When are head computed tomography and skull radiographs indicated?. *Pediatrics* 1997;99(5):E11.  
[Google Scholar](#)    [Crossref](#)    [PubMed](#)
15. Reed MJ, Browning JG, Wilkinson AG, Beattie T Can we abolish skull X-rays for head injury? *Arch Dis Child* 2005;90(8):859–64.  
[Google Scholar](#)    [Crossref](#)    [PubMed](#)
16. Greenes DS, Schutzman SA Clinical significance of scalp abnormalities in asymptomatic head-injured infants. *Pediatr Emerg Care* 2001;17(2):88–92.  
[Google Scholar](#)    [Crossref](#)    [PubMed](#)
17. Schutzman SA, Barnes P, Duhaime AC, et al. Evaluation and management of children younger than two years old with apparently minor head trauma: Proposed guidelines. *Pediatrics* 2001;107(5):983–93.  
[Google Scholar](#)    [Crossref](#)    [PubMed](#)
18. Thiessen ML, Woolridge DP Pediatric minor closed head injury. *Pediatr Clin North Am* 2006;53(1):1–26.  
[Google Scholar](#)    [Crossref](#)    [PubMed](#)
19. Brenner DJ, Hall EJ Computed tomography: An increasing source of radiation exposure. *NEJM* 2007;357(22):2277–84.  
[Google Scholar](#)    [Crossref](#)    [PubMed](#)
20. Maguire JL, Boutis K, Uleryk EM, Laupacis A, Parkin PC Should a head-injured child receive a head CT scan? A systematic review of clinical prediction rules. *Pediatrics* 2009;124(1):e145–54.

[Google Scholar](#)   [Crossref](#)   [PubMed](#)

21. Pickering A, Harnan S, Fitzgerald P, Pandor A, Goodacre S Clinical decision rules for children with minor head injury: A systematic review. *Arch Dis Child* 2011;96(5):414-21.
22. Kuppermann N, Holmes JF, Dayan PS, et al. ; for the Pediatric Emergency Care Applied Research Network (PECARN) Identification of children at very low risk of clinically-important brain injuries after head trauma: A prospective cohort study. *Lancet* 2009;374(9696):1160-70.  
[Google Scholar](#)   [Crossref](#)   [PubMed](#)
23. Parkin PC, Maguire JL Clinically important head injuries after head trauma in children. *Lancet* 2009;374(9696):1127-9.  
[Google Scholar](#)   [Crossref](#)   [PubMed](#)
24. Osmond MH, Correl R, Stiell IG, et al. Multicenter prospective validation of the Canadian Assessment of Tomography for Childhood Head Injury (CATCH) Rule. *E PAS*2012:3155.4.
25. Sanford RA Prevention of growing skull fractures. *J Neurosurg Pediatrics* 2010;5(2):213-8.  
[Google Scholar](#)   [Crossref](#)
26. Kochanek PM, Carney N, Adelson PD, et al. ; American Academy of Pediatrics, Section on Neurological Surgery; American Association of Neurological Surgeons, Congress of Neurological Surgeons; Child Neurology Society; European Society of Pediatric and Neonatal Intensive Care; Neurocritical Care Society; Pediatric Neurocritical Care Research Group; Society of Critical Care Medicine; Paediatric Intensive Care Society UK; Society for Neuroscience in Anesthesiology and Critical Care; World Federation of Pediatric Intensive and Critical Care Societies Guidelines for the Acute Medical Management of Severe Traumatic Brain Injury in Infants, Children and Adolescents-Second Edition. *Pediatr Crit Care Med* 2012;13(Supp 1):S1-82.  
[Google Scholar](#)   [PubMed](#)
27. Meyer P, Marchal J-C, Hutchison JS, et al. Traumatisme crânien grave. In : Lacroix J, Gauthier M, Hubert P, Leclerc F, Gaudreault P Urgences et soins intensifs pédiatriques, 2nd edition. Montréal : Éditions du CHU Sainte-Justine & Masson, 2007 : 901-31.  
[Google Scholar](#)

28. Chiaretti A, De Benedictis, Polidori G, Piastra M, Iannelli A, Di Rocco C Early post-traumatic seizures in children with head injury. *Childs Nerv Syst* 2000;16(12):862-6.  
[Google Scholar](#)   [Crossref](#)   [PubMed](#)
  
29. Hahn YS, Fuchs S, Flannery AM, Barthel MJ, McLone DG Factors influencing posttraumatic seizures in children. *Neurosurgery* 1988;22(5):864-7.  
[Google Scholar](#)   [Crossref](#)   [PubMed](#)
  
30. Barlow KM, Spowart JJ, Minns RA Early posttraumatic seizures in non-accidental head injury: Relation to outcome. *Dev Med Child Neurol* 2000;42(9):591-4.  
[Google Scholar](#)   [Crossref](#)   [PubMed](#)
  
31. Holmes JF, Palchak MJ, Conklin MJ, et al. Do children require hospitalization after immediate posttraumatic seizures?. *Ann Emerg Med* 2004;43(6):706-10.  
[Google Scholar](#)   [Crossref](#)   [PubMed](#)
  
32. Friedman J; Canadian Paediatric Society, Acute Care Committee Emergency management of the paediatric patient with generalized convulsive status epilepticus. *Paediatr Child Health* 2011;16(2):91-7.  
[Google Scholar](#)   [Crossref](#)   [PubMed](#)
  
33. Young KD, Okada PJ, Sokolove PE, et al. A randomized, double-blinded, placebo controlled trial of phenytoin for the prevention of early posttraumatic seizures in children with moderate to severe blunt head injury. *Ann Emerg Med* 2004;43(4):435-6.  
[Google Scholar](#)   [Crossref](#)   [PubMed](#)
  
34. Young B, Rapp RP, Norton JA, Haack D, Walsh JW Failure of prophylactically administered phenytoin to prevent post-traumatic seizures in children. *Childs Brain* 1983;10(3):185-92.  
[Google Scholar](#)   [PubMed](#)
  
35. Purcell L; Canadian Paediatric Society, Healthy Active Living and Sports Medicine Committee Evaluation and management of children and adolescents with sports-related concussion. *Paediatr Child Health* 2012;17(1):31-2.  
[Google Scholar](#)   [Crossref](#)   [PubMed](#)
  
36. Fraser DD, Close TE, Rose KL, et al. ; for the Canadian Critical Care

Translational Biology Group Severe traumatic brain injury in children elevates glial fibrillary acidic protein in cerebrospinal fluid and serum. *Pediatr Crit Care Med* 2011;12(3):319–24.

[Google Scholar](#)   [Crossref](#)   [PubMed](#)

37. Guerguerian AM, Lo TY, Hutchison JS Clinical management and functional neuromonitoring in traumatic brain injury in children. *Curr Opin Pediatr* 2009;212(6):737–44.

[Google Scholar](#)   [Crossref](#)

38. Levin HS, Hanten G, Roberson G, et al. Prediction of cognitive sequelae based on abnormal computed tomography findings in children following mild traumatic brain injury. *J Neurosurg Pediatr* 2008;1(6):461–70.

[Google Scholar](#)   [Crossref](#)   [PubMed](#)

39. Canadian Paediatric Society Are We Doing Enough? A status report on Canadian public policy and child and youth health. Ottawa: Canadian Paediatric Society, 2012.

[Google Scholar](#)

**Disclaimer:** The recommendations in this position statement do not indicate an exclusive course of treatment or procedure to be followed. Variations, taking into account individual circumstances, may be appropriate. Internet addresses are current at time of publication.

© 2001 – 2016 Canadian Paediatric Society. All rights reserved

The Canadian Paediatric Society gives permission to print single copies of this document from our website. For permission to reprint or reproduce multiple copies, please see our copyright policy.

© 2001 – 2016 Canadian Paediatric Society. All rights reserved

## Supplementary data

---

[Management-of-the-paediatric-patient-with-acute-head-trauma-2013-18-5-253](#) - zip file